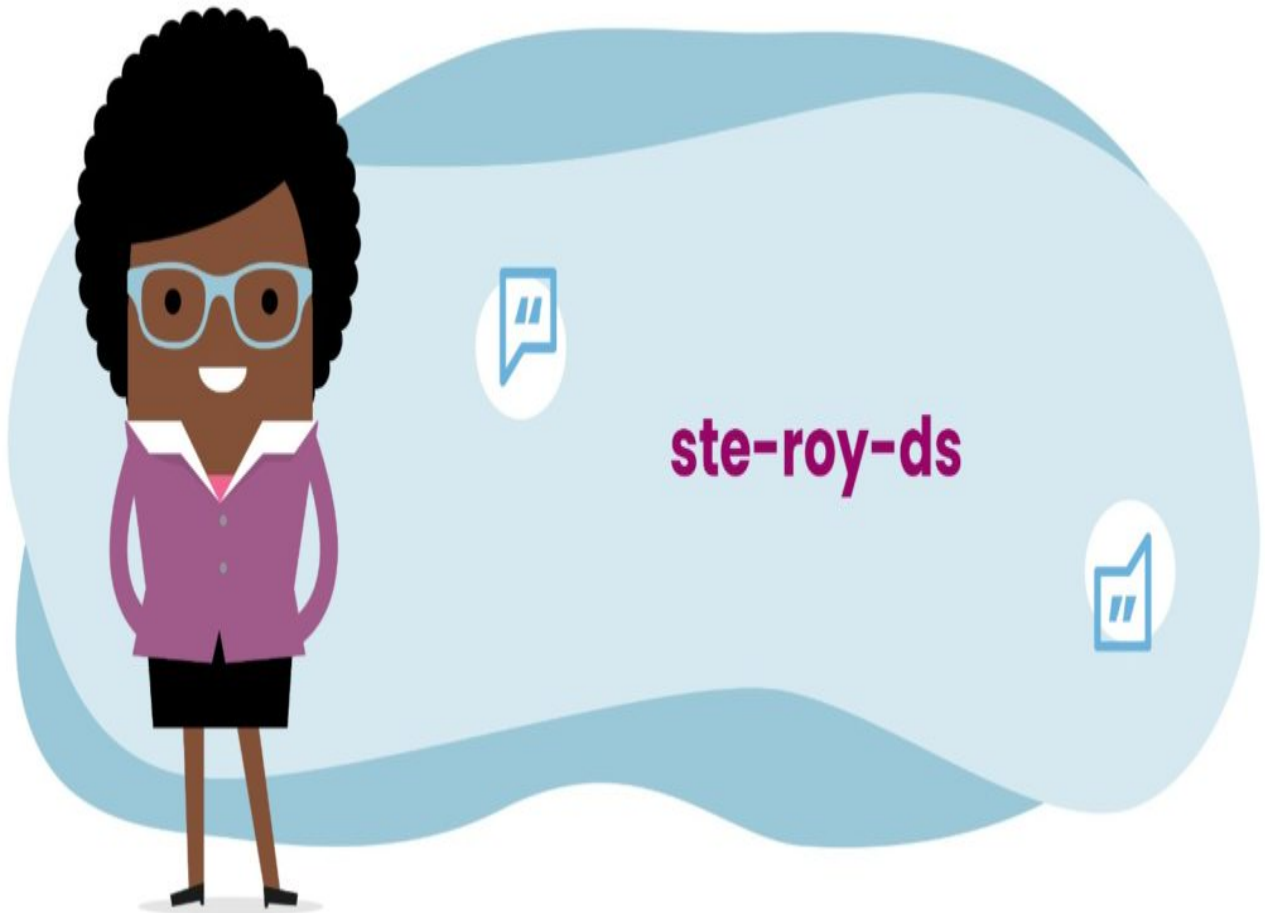


Steroid injections

[Print](#)



Introduction

Intra-articular steroid injections (IAS) are frequently used as first line treatment in Juvenile Idiopathic Arthritis (JIA). As such, IAS may be considered as medication to induce remission in inflamed joints, and for some patients IAS may be the only medical treatment that is required, usually those with a small number of inflamed joints (oligoarthritis). For others with several joints involved (polyarticular JIA), IAS can help to provide rapid relief of symptoms whilst other systemic medical treatments such as conventional DMARDs (disease modifying anti-rheumatic drugs) such as methotrexate or biologic therapies are becoming effective. It is possible to repeat IAS as required, but doctors may limit the

amount of injections to individual joints over certain time periods.

IAS injections can be performed using different methods of analgesia (pain relief) to ensure the procedure is as comfortable as possible. Younger children will often require a short general anaesthetic to allow the procedure to take place, whereas older children may be able to cope with local anaesthetic (such as Ametop cream, EMLA cream or lidocaine injection) alongside nitrous oxide commonly called “Entonox” (sometimes referred to as “laughing gas”).

The procedure should always be carried out by a health professional and team skilled in the technique of injection with access to the methods of pain relief described above. It is important to assess which joints need injecting at the time of the procedure as this may change from the initial assessment.

Choice of medicine for IAS

There are several options available. Most hospitals use triamcinolone hexacetonide injected into the joint as it is very long-lasting. Some hospitals may use triamcinolone acetonide as an alternative when injecting smaller joints such as fingers, jaw or tendons as there is less risk of subcutaneous atrophy (see later).

Techniques used for IAS



The most important aspect is that the health professional delivering the IAS is appropriately trained to do so in children and young people. It may be a doctor, a trained nurse or physiotherapist.

Injection into some joints, for example the hip or subtalar joint, will require an X-ray or ultrasound to confirm the correct placement of the needle in the joint. If it is possible to remove any excessive fluid from the joint at the same time, this will usually be done.

The plan for the procedure should always be explained to the patient and carer prior to it taking place. If the procedure is to be performed under a general anaesthetic, the anaesthetist will also talk to you about what is involved and any risks. For IAS performed with local anaesthetic, support from nurses or play therapists may be available to ensure the experience is as comfortable as possible.

Management after IAS

This will vary according to individual cases. Most hospitals will recommend a brief period of relative rest, not necessarily bed-rest, usually for no more than 24 hours, before resuming normal activities. Some children and young people will require physiotherapy after IAS to restore joint and muscle function. Splinting of joints after IAS is occasionally recommended.

If a joint is painful after IAS this will usually settle quickly with rest and simple painkillers such as

paracetamol or ibuprofen. If the symptoms do not settle or the patient is unwell, especially with fever, then medical advice should be sought.

Side effects after IAS

Fortunately side effects are rare after IAS. The most significant side effects to be aware of are as follows:

1. Infection

There is an extremely small risk of an infection developing in a joint after IAS, so the health professional administering the injection will always take great care to use a sterile technique when performing IAS.

2. Subcutaneous fat atrophy

After some IAS subcutaneous fat atrophy can occur. This is more common if the IAS is for a smaller joint, such as fingers, wrists or subtalar joint, and is very rare for example after injection of the knees. This occurs when some of the steroid medicine leaks into the tissues under the skin and causes damage to fat cells. It is not dangerous or painful but it can cause an unusual appearance such as whitening or indentation of the skin. This is not usually visible immediately and takes a few months to evolve. Careful technique and use of X-rays ensuring the steroid is injected in the correct place when necessary can minimise this risk.

3. Calcification

Occasionally after IAS small flecks of calcification can be seen on later X-rays of joints. Usually this is of no significance and is a coincidental finding because the X-ray has been done for another reason. No further action is necessary.

4. Steroid absorption

Whilst the primary effect of the IAS is reduction in inflammation of the joint, some of the steroid is absorbed into the body. If larger doses of triamcinolone acetonide are used because many joints are injected this can cause a temporary "cushingoid" appearance with swelling and flushing of the face. This is not usually harmful but the team treating the patient should be made aware as the patient should be considered temporarily immunosuppressed.

Updated: 18/10/2019